

Original Article

How to Overcome the Challenges of Non-Detachable Connector Tubes in Submental Intubation for Panfacial Fractures

Sahand Samieirad¹, Hussein Khalife², Mehrdad Noroozi³, Elahe Tohidi⁴, Maryam Alsadat Hashemipour⁵

Abstract

Introduction: Armored removable connector tubes are not always available in operating rooms for routine Altemir submental intubation (SMI) technique. The present study addresses a fiber-optic glidoscopy assisted 2-tubes modification of Green & Moore sequence for submandibular intubation.

Methods: The sample was composed of 11 patients (8 males and 3 females) with panfacial fractures where neither the oral and nasal intubation techniques nor tracheostomy were feasible. The inter-operative procedure duration was recorded and a comparison was made between the present results with those obtained in similar studies. Moreover, postoperative complications were assessed over a duration of 6 months.

Results: The average duration of this modified procedure was 8–13 min. (Mean, 10.54 ± 1.75 min). No perioperative or postoperative complications were observed. Based on the findings in this study, it is suggested that this new technique is safe, quick and reliable for submandibular intubation.

Conclusion: This modification establishes a secure airway for treatment of maxillofacial panfacial fractures, where traditional methods are impossible due to non-detachable connector tubes. No perioperative or postoperative complications were observed. This study suggests that this new technique is safe, quick and reliable for submandibular intubation.

Keywords: Altemir technique, Green & Moore technique, panfacial fractures, submental intubation

Cite this article as: Samieirad S, Khalife H, Noroozi M, Tohidi E, Hashemipour MA. How to Overcome the Challenges of Non-Detachable Connector Tubes in Submental Intubation for Panfacial Fractures. *Arch Iran Med.* 2017; 20(8): 481–486.

Introduction

Airway management in cases of maxillofacial surgery requires special considerations and is challenging to anesthesiologists. Different methods of intubation and surgical airway management have been proposed in the medical literature.¹⁻¹⁰

In maxillofacial surgeries, there is frequent need for maxillomandibular fixation (MMF). Consequently, using orotracheal intubation significantly interferes with occlusion checking during surgery.^{1,3,5}

Submental intubation (SMI) is considered an alternative to tracheostomy during surgical repair of severe craniomaxillofacial trauma, particularly when neither nasal nor orotracheal intubation are suitable.^{1,5,11}

Unfortunately, routine Altemir submental intubation cannot be performed with non-removable connector tubes. Anesthesiologists usually prefer non-detachable connector tubes for their routine practice. Thereby, armored removable connector

tubes are not always available in operating rooms. Consequently, limited modifications have been suggested to perform SMI with non-detachable connector tubes.^{2,11,12} Since these modifications have some drawbacks,^{1,2,4,11,13,14} we introduce a new fiber-optic glidoscopy assisted 2-tubes modification of Green & Moore sequence for submental intubation in the present research.

Materials and Methods

Eleven patients with panfacial fractures demanding ORIF (open reduction and internal fixation) were the candidates for submandibular intubation in this study. These patients were admitted to the maxillofacial surgery department of Kerman Bahonar hospital and Mashhad Kamyab hospital from January 2014 to November 2015.

The study was approved by the Institutional Human Research and Ethics Committee of our hospital (Ethical approval IR.mums.sd.Rec.1392). After detailed discussion, informed written consent was obtained from each patient or their legal guardians.

The age, sex and fracture types of the patients are listed in Table 1. Patients with a tracheostomy tube, those requiring prolonged assisted ventilation post-operatively (more than 72 h), and comatose patients were excluded from the study. All intubations were done with non-detachable connector tubes (Mallinckrodt tube) aided with fiber-optic glidoscopy (Figure 1)

Inclusion criteria

All patients with panfacial fractures (Le Fort fracture with

Authors' affiliations: ¹Oral and Maxillofacial Surgery Department, Mashhad Dental School, Oral and Maxillofacial Disease Research Center, Mashhad University of Medical Sciences, Mashhad, Iran. ²Private Practice Beirut Lebanon. ³Anesthesiology Department, Kerman University of Medical Sciences, Kerman, Iran. ⁴Oral and Maxillofacial Radiology Department, Mashhad Dental School, Mashhad University of Medical Sciences, Mashhad, Iran. ⁵Department of Oral Medicine, Dental School, Kerman University of Medical Science, Kerman, Iran.
***Corresponding author and reprints:** Maryam Alsadat Hashemipour, Kerman dental School, Shafa Street, Kerman, Iran. Fax: 00983412118073, Phone: +989132996183, +983432118073, E-mail: m_s_hashemipour@yahoo.com
 Accepted for publication: 20 July 2017

Table 1. Age, sex, maxillofacial fracture type, SMI procedure and operation duration in eleven patients.

Case No	Sex	Age	Maxillofacial Fx type	CSF leakage	Duration of SMI procedure	Postoperative ventilation	Duration of maxillofacial surgery
1	M	28	Bilateral Subcondylarfx, Lt ZMC fx, Nasal bone fx Lefort II fx.	No	10 min	No	9 hour
2	M	32	Lefort III fx, Nasal bone fx	No	12 min	No	7 hour
3	F	30	Skull base fx, Rt mandibular angle fx, Lefort I fx	Yes	13 min	No	4 hour
4	M	22	NOE fx, Bilateral ZMC fx	No	8 min	No	6 hour
5	M	24	Lefort III fx	No	10 min	No	7 hour
6	F	27	Lefort III fx, NOE fx	No	10 min	Yes (only for 15 hours)	10 hour
7	M	25	Skull base fx, Mandibular symphysis fx Rtsubcondylar fx	Yes	10 min	No	5 hour
8	F	40	Comminuted Palatal fx, Lefort I fx, Nasal bone fx	No	8 min	No	3 hour
9	M	35	Skull base fx Ant table frontal sinus fx, Lefort II fx	Yes	13 min	No	5 hour
10	M	42	Rt ZMC fx, Lefort I fx, Nasal bone fx	No	10 min	No	6 hour
11	M	34	Lefort III fx	No	12 min	No	5 hour

M = male, F = female, Rt = right, Lt = left, NOE = naso-orbito-ethmoidal.; ZMC = zygomatico maxillary complex, Ant = anterior, Fx = fracture.

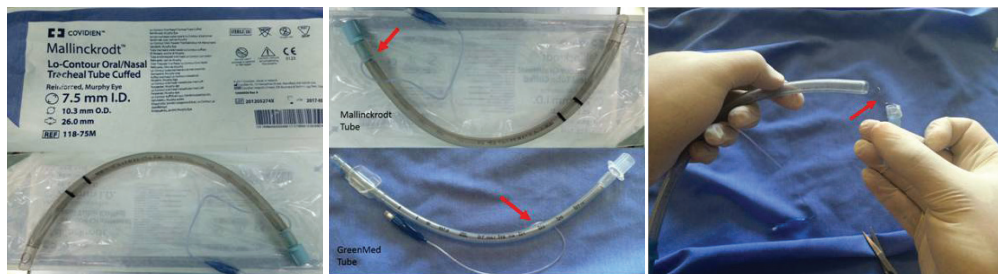


Figure 1. Mallinckrodt Tube.

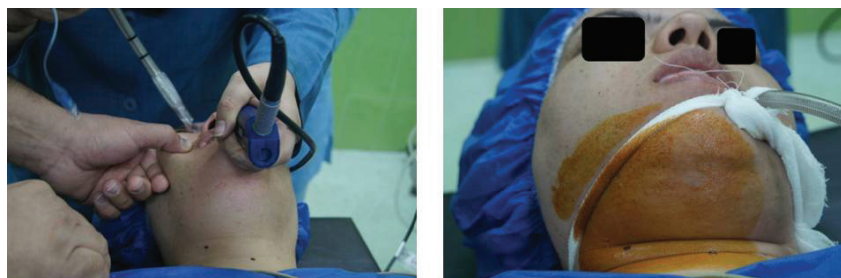


Figure 2. Preparation of Patient for operation.

mandibular and nasal fractures), requiring ORIF treatment (open reduction and internal fixation) were candidates for submandibular intubation in this study.

Exclusion criteria

The likelihood that a patient had a tracheostomy tube, required prolonged assisted ventilation post-operatively (more than 72 h), and comatose patients.

Operative technique

Green & Moore sequence was upgraded here to perform submandibular intubation with non-detachable connector tubes, to eliminate the drawbacks of the conventional method (Figures 1 and 2).

Under general anesthesia, an armored non-detachable orotracheal tube was introduced using a fiber-optic glidoscope. A 2-cm submandibular incision, instead of submental, was made close to the lower border of the mandible.

Blunt dissection was carried out in the submandibular region as closely as possible to the inner aspect of the mandible into the floor of the mouth using Kelly forceps (Figure 3).

The mucosal layer was then incised at the floor of mouth allowing the passage of a second tracheal tube. Afterwards, a tunnel was created using Kelly forceps.

Dissection care should be taken with any damage to the submandibular duct, facial and lingual nerve. The second step was introducing a Kelly forceps from the floor of mouth out through the extraoral incision to grasp a second reinforced non-detachable tube.

The new tube would now be drawn and passed through the incision from the extraoral region into the mouth. Finally, the

second tube was pulled into the mouth through the incision from outside to inside, while the first tube was securing the airway properly (Figure 1).

It is worth mentioning that the cuff of the second tube was not grasped during this maneuver (remained intact outside). The first original oral tube was withdrawn gradually and replaced by the second tube conservatively. This third step was done guided by fiber-optic glidoscopy (Figure 4).

The fiber-optic glidoscopy was applied in this technical note to eliminate any vigorous manipulation of the armored tracheal tube with the Magill forceps, as seen in direct laryngoscopy in Green & Moore SMI sequence. Finally, the cuff was inflated and a throat pack was inserted. Silk sutures were placed at the submandibular skin to stabilize the tube. At the end of the procedure, extubation was performed for any normally intubated patient and the extraoral incision was sutured (Figures 5).

Finally, no obvious hypertrophy scar was observed in patients after 6 months (Figure 6).

Results

In our case series of eleven patients, fiber-optic glidoscopy with the tubes substitution was used successfully in order to perform submental intubation with non-detachable connector Mallinckrodt tubes. In all patients, submental intubation allowed for simultaneous reduction and fixation of all fractures. Furthermore, intraoperative control of dental occlusion was made possible without interference from the tube during the operation.

This study consisted of eight male and three female patients, aged 22 to 42 years (mean, 30.8 ± 6.47 year). Several types of craniomaxillofacial fracture which precluded both nasal and oral

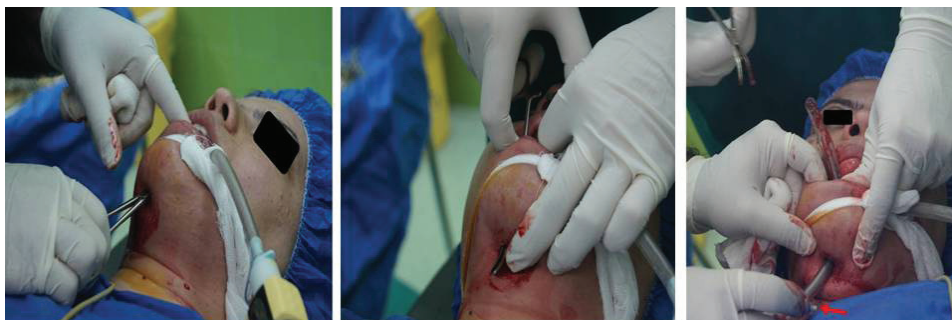

Figure 3. Performing the submandibular incision and blunt dissection close to the lower border of mandible, the second tube was grasped by Kelly forceps and pulled into the mouth from exterior to interior, while the first tube was in trachea property (Note that the cuff is not grasped).

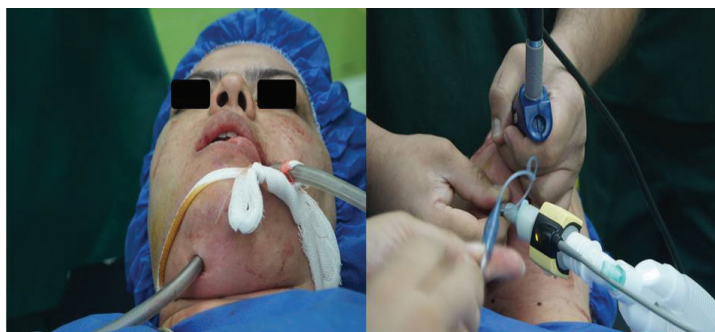

Figure 4. The second non-detachable connector tube substituted the first oral one conservatively with the aid of fiber-optic glidoscopy. (consider this new 2-tubes technique and also tubes position before the substitution).

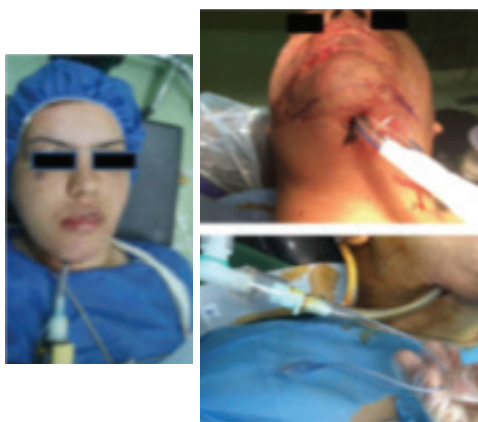

Figure 5. Extubation was performed for any normally intubated patient and the extraoral incision is sutured.

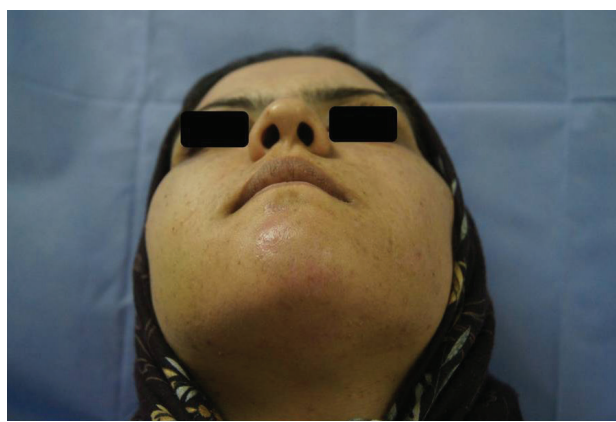

Figure 6. No obvious hypertrophic scars were observed in patients after 6 months.

intubation were observed. In addition, three patients had CSF leakage due to skull base trauma. The craniomaxillofacial fracture types, patients' age, sex and other information regarding the SMI intubation and maxillofacial procedure duration are listed in Table 1. The average duration of this SMI modification procedure was 8–13 min. (mean, 10.54 ± 1.75 min). The maxillofacial surgical operation in these cases lasted 3 to 10 hours. (mean 6 ± 2.07 hours). Only one patient needed 15 hours of postoperative ventilation in ICU according to the anesthesiologist's order, due to prolonged operation time (approximately 10 hours).

All the other 10 patients were extubated at the end of operation without any problems. The postoperative follow up visits continued for at least 6 months, and no postoperative complications were reported.

The follow up showed no injury to any of the adjacent vital structures and no motor or sensory deficits were found (lingual nerve and facial nerve functions were intact). Moreover, no bleeding, infection, submandibular gland mucocele or salivary gland fistula were found.

Healing of skin wound was almost perfect and normal healing of the intraoral mucosa was observed. The patients were fully satisfied with the submandibular skin scar, and no cases of hypertrophic scarring were found in our study (Figure 3).

During the procedure, no additional difficulties were encountered in passing the tube through the floor of the mouth.

The ventilation disconnection time with substituting the 2 tubes was less than 30 sec. No significant oxygen desaturation was observed in any patient during the procedure. The surgeons found the new technique simple and safe. Furthermore, the anesthesiologists were comfortable with this maneuver as tube cuff damage or hypoxia did not occur in this sequence. Finally, avoiding tracheostomy using this technique granted satisfaction to all patients.

Discussion

Anesthesia of maxillofacial patients entails unique airway challenges requiring experienced and skillful cooperation of maxillofacial surgeons and anesthesiologists.^{2,4,13}

Submental intubation was first reported by Altemir in 1986 as a safe procedure that could avoid tracheostomy.¹⁵ It is now a

recognized technique for airway control in severe maxillofacial injuries. It leads to the reduction of facial fractures and restoration of occlusion concomitant with intraoperative MMF without compromising the airway.^{1,13}

Furthermore, the SMI method is recently preferred in cases where panfacial and concomitant Naso-Orbital Ethmoidal fractures (NOE) are treated and also in some case of orthognathic surgery with severe septal deviations.^{1,2,4,13,16-19}

The significantly increasing number of PubMed articles about SMI in the last 10 years, compared to the past two decades, confirms the recent uptrend towards performing this technique.

Altemir's original SMI technique used detachable non-armored oral tube. This one-tube technique involves the passage of the detached tube post intubation from inside to outside through a submental incision.¹⁵

SMI incision could be in the midline, submental triangle or submandibular region depending on the site of injury or the surgeon's preference.^{1,2,13}

The submandibular approach is recommended as it has had fewer complications than others.² As a matter of fact, the technique introduced in this article utilized the submandibular incision.

SMI maneuver is better performed by using a reinforced tube, where its universal connector is removed easily for tube passage through the submental incision.

Unfortunately, most of the operating rooms are equipped with non-detachable connector armored tubes, as preferred for routine use by anesthesiologists. It is found that these tubes are not the choice for conventional Altemir technique.^{1,2,11-13}

Different modifications have been published to overcome the challenge of non-removable connector tubes.^{1,2,6-12} Some proposed cutting the tube connector to allow the passage from the submental incision, followed by taping with Leukoplast. However, this procedure was not considered as a preferred choice as it would lead to the awkward exposure of the tube's internal wire prohibiting perfect adaptation of the connector again.^{2,14}

Furthermore, cutting the tube at the connector level would lead to serious cuff damaging, obviously causing dangerous complications (Figure 4).

The major methods dealing with non-detachable connector tubes are presented in Table 2. The most substantial modification of SMI with non-detachable connector tubes was actually

Table 2. Modified submental intubation methods performed with non-detachable connector tubes.

The author name	Year	The modified method to perform Submental intubation with non-detachable connector reinforced tubes	Drawbacks
Green and Moore	1996	Submental incision Using 2 tubes and direct laryngoscopy with Magill forceps manipulation	1. Possible cuff damage due to vigorous manipulation of Magill forceps. 2. Difficult and time consuming procedure 3. Traumatic airway complications due to direct and complicated laryngoscopy 4. More complications due to submental incision.
Drolet <i>et al.</i>	2000	Submental incision Using 2 tubes and tube exchanger	1. Difficulty of tube exchanger application in the case of steep angle insertion imposed by the submental approach. 2. Complications due to submental incision.
Anwer <i>et al.</i>	2007	Submandibular incision 1 tube technique Removal of the fixed connector with mosquito forceps before SMI procedure making it removable	1. The connector would be possibly loose and ill-fitting after reconnection in case of forceful removal of the non-detachable connector. 2. Possible cuff damage in 1-tube technique when pulling the tube from intraoral to extraoral position
Current study	2016	Submandibular incision Using 2 tubes and Fiber-optic glidoscopy with conservative manipulation	Need for operating room fiber optic glidoscope

described by Green and Moore in 1996.¹² It involved the use of two endotracheal tubes, where the first oral tube is replaced by a second one introduced through the submental incision. The first tube secures the patient's airway whereas a second armored non-detachable tube is passed through the incision, from exterior to interior. The second tube is manipulated and grabbed with Magill forceps during direct laryngoscopy into the trachea just after the removal of the first one.^{1,2,11-13}

The main disadvantage of this technique is that the cuff of the tracheal tube can be damaged during vigorous manipulation by the Magill forceps. Moreover, this technique is considered to be a time consuming procedure due to direct and complicated laryngoscopy with multiple tries which may cause postoperative traumatic airway complications.^{1,2,11,13} In addition, Green and Moore's technique uses the submental incision for the passage of the tube. According to the literature, the submental incision in SMI entails more complications in comparison to the submandibular incision.^{2,13}

In an effort to overcome the problem of the irremovable connector, Drolet and colleagues used tube exchangers to replace the damaged submental tracheal tube with a fresh reinforced armored one.¹¹ The tube exchanger is a semi-rigid catheter that can be also used as a tracheal ventilation device to facilitate the replacement of nasal and orotracheal tubes.^{2,11,13}

Drolet's technique has an obvious limitation, as the tube exchanger may not be applied properly, in the case of steep angle insertion imposed by the submental approach. Secondly, this technique, similar to Green and Moore's technique, has the drawback of submental incision.^{2,13}

In 2007, Anwer *et al.* proposed a one-tube SMI technique where the non-detachable connector tube could be smoothly transformed into a fitting removable one. The process was done by removal of the fixed connector using a mosquito forceps before starting the SMI procedure.²

One of the drawbacks of this method is that the removal of the non-detachable connector could be forceful, leading to an ill-fitting connector. As a result, the connector will stay dangerously loose after reconnection^{4,11,13} (Figure 5). Moreover, simultaneous

passage of the tube with its cuff in one step with one forceps, through the submandibular incision, may have the risk of damaging the cuff, especially in short incisions. Therefore, Savitha *et al.* in 2016 proposed the use of two Kelly forceps to overcome this problem.¹³ Furthermore, as reported in the literature, the risk of deoxygenation in one-tube techniques is greater compared to two-tube procedures.^{1,2,5}

Appreciating the good concept of conventional Green & Moore's technique, the author felt a necessity to upgrade this method to circumvent its major mentioned drawbacks.^{1,2,11,13} The purpose of our new two-stage fiber-optic assisted SMI are listed below.

Firstly, there is smaller risk of accidental extubation^{1,2} or compromising the patient's airway if difficulty is encountered during re-attachment or passing the tube through the incision.¹² Secondly, due to the irremovable design of non-detachable tube connectors, this modified method helps to perform SMI without the need for cutting the tube or forceful connector removal, leading to connector loosening and hypoxia.¹² Thirdly, aided with fiber-optic glidoscopy instead of direct laryngoscopy, aggressive grabbing of tube by Magill forceps and excessive traumatization of the airway can be avoided.^{2,11} Moreover, glidoscopy facilitates the exchange of the two tubes by keeping the oropharynx open, as well as rapid identification of anatomical landmarks by the operator.^{20,21}

Finally, making a submandibular, instead of submental, incision is considered more advantageous for being distant from vital anatomic landmarks with a less conspicuous scar.^{1,2,5}

The authors acknowledge that using two tubes increases the duration of submandibular intubation compared to using a single tube in conventional Altemir technique.^{1,2,4,5} However, using two tubes aided with fiber-optic glidoscopy minimizes the possibility of accidental extubation (seen in one-tube methods)² and the time needed for the intubation procedure (classic Green and Moore).^{1,12} Referring to the medical literature, the duration of the SMI procedure ranges from less than 4 min to 30 min in different methods, with an average 9.9 min in conventional one-tube technique.^{1,4,18} The mean duration of modified submandibular intubation with fiber-optic in our study was 10.54 minutes, which

is significantly close to the results of one-tube techniques.^{4,12} Therefore, the duration of our modified SMI procedure may be considered acceptable with 2-tube sequence compared to the outcomes mentioned in the literature.^{1,3}

Moreover, neither a conspicuous scar was found in our patients, nor any complications were observed with our technique. A possible drawback of the technique proposed by the authors could be the shortage of armamentarium, such as fiber optic glidoscope, in some operating rooms.

In conclusion, this modified fiber-optic assisted Green & Moore technique may be considered a safe, rapid and reliable submandibular intubation method for establishing an airway in panfacial fractures with non-detachable connector tubes.

Conflict of Interest: None.

Funding: None.

Acknowledgment

The authors appreciate the support of Maxillofacial Surgery and Anesthesiology Departments of Kerman and Mashhad Medical Universities, Iran.

References

- Jundt JS, Cattano D, Hagberg CA, Wilson JW. Submental intubation: a literature review. *Int J Oral Maxillofac Surg.* 2012; 41(1): 46 – 54.
- Anwer HM, Zeitoun IM, Shehata EA. Submandibular approach for tracheal intubation in patients with panfacial fractures. *Br J Anaesth.* 2007; 98(6): 835 – 840.
- Caubi AF, Vasconcelos BC, Vasconcelos RJ, de Morais HH, Rocha NS. Submental intubation in oral maxillofacial surgery: review of the literature and analysis of 13 cases. *Med Oral Patol Oral Cir Bucal.* 2008; 13(3): E197 – E200.
- Kita R, Kikuta T, Takahashi M, Ootani T, Takaoka M, Matsuda M, et al. Efficacy and complications of submental tracheal intubation compared with tracheostomy in maxillofacial trauma patients. *J Oral Sci.* 2016; 58(1): 23 – 28.
- Thomas S, Vaithilingam Y, Sundararaman P, Thukral R, Pasupathy S. Submental intubation in maxillofacial surgery: a prospective study. *J Maxillofac Oral Surg.* 2013; 12(3): 248 – 253.
- Shivpuri A. Sub-mental Intubation in Oral and Maxillofacial Trauma Patients. *Indian J Surg.* 2015; 77 (Suppl 3): 1450 – 1452.
- Jin H, Patil PM. Midline submental intubation might be the preferred alternative to oral and nasal intubation in elective oral and craniomaxillofacial surgery when indicated. *J Oral Maxillofac Surg.* 2015; 73(1): 39 – 46.
- Prakash VJ, Chakravarthy C, Attar AH. Submental/Transmylohyoid route for endotracheal intubation in maxillofacial surgical procedures: a review. *J Int Oral Health.* 2014; 6(3): 125 – 128.
- Eisemann B, Eisemann M, Rizvi M, Urata MM, Lypka MA. Defining the role for submental intubation. *J Clin Anesth.* 2014; 26(3): 238 – 242.
- O'Connell JE, Kearns GJ. Submental intubation: a retrospective review of 45 cases. *Irish J Med Sci.* 2013; 182(3): 309 – 313.
- Drolet P, Girard M, Poirier J, Grenier Y. Facilitating submental endotracheal intubation with an endotracheal tube exchanger. *Anesth Analg.* 2000; 90(1): 222 – 223.
- Green JD, Moore UJ. A modification of sub-mental intubation. *Br J Anaesth.* 1996; 77(6): 789 – 791.
- Savitha KS, Kujur AR, Vikram MS, Joseph S. A modified submental orotracheal intubation. *Anesth Essays Res.* 2016; 10(1): 132 – 135.
- Amin M, Dill-Russell P, Manisali M, Lee R, Sinton I. Facial fractures and submental tracheal intubation. *Anaesth.* 2002; 57(12): 1195 – 1199.
- Altemir FH. The submental route for endotracheal intubation. A new technique. *J Maxillofac Surg.* 1986; 14(1): 64 – 65.
- Junior JM, Kluppel LE, Pereira Stabile CL, Vitti Stabile GA. Submental endotracheal intubation as an alternative to tracheostomy in selected cases of facial fracture: literature review and technique report. *Ulus Travma Acil Cerrahi Derg.* 2012; 18(6): 545 – 548.
- Vashishta A, Sharma S, Chugh A, Jain D, Gupta N, Bihani U. Submental intubation: A useful adjunct in panfacial trauma. *Natl J Maxillofac Surg.* 2010; 1(1): 74 – 77.
- Gadre KS, Waknis PP. Transmylohyoid/Submental intubation: review, analysis, and refinements. *J Craniofac Surg.* 2010; 21(2): 516 – 519.
- Ibrahim A, Balakrishnan R, Ebenezer V, Padmanabhan A, Muthlingam V. Combating nasal septum deviation in le fort I orthognathic surgery complications, with submental intubation. *J Clin Diagn Res.* 2014; 8(6): ZC46 – ZC48.
- Gu J, Xu K, Ning J, Yi B, Lu K. Glide Scope-assisted fiberoptic bronchoscope intubation in a patient with severe rheumatoid arthritis. *Acta Anaesthesiol Taiwan.* 2014; 52: 85 – 87.
- Doyle DJ. Glide Scope®-assisted fiberoptic intubation: a new airway teaching method. *Anesthesiology.* 2004; 101: 1252.