

## Original Article

# Effect of Tricuspid Valve Repair in Patients with Moderate Tricuspid Regurgitation undergoing Left-Sided Valve Surgery

Fahime Abdollahi, MD<sup>1</sup>; Masoumeh Lotfi-Tokaldany, MD<sup>1</sup>; Arash Jalali, PhD<sup>1</sup>; Mohammad Moein Ashrafi<sup>2</sup>; Abbas Mohagheghi, MD<sup>3</sup>; Afsaneh Sadeghian, MD<sup>4</sup>; Hakimeh Sadeghian, MD<sup>3\*</sup>

<sup>1</sup>Tehran Heart Center, Tehran University of Medical Sciences, Tehran, Iran

<sup>2</sup>Young Researchers and Elites Club, Faculty of Medicine, Islamic Azad University, Yazd Branch, Yazd, Iran

<sup>3</sup>Echocardiography Department, Dr. Shariati Hospital, Tehran University of Medical Science, Tehran, Iran

<sup>4</sup>Bahar Hospital, Shahrood University of Medical Science, Shahrood, Iran

## Abstract

**Background:** The benefits of tricuspid valve (TV) repair in patients with moderate tricuspid regurgitation (TR) during left-sided valve surgery are under debate. We investigated independent predictors for reduction in TR severity following left-sided valve surgery in patients with moderate TR.

**Methods:** In this study, we included 106 patients (male: 33%) with a mean age of  $4.23 \pm 12.61$  years who had moderate TR and underwent mitral or aortic valve surgery between March 2012 and November 2016. Concomitant tricuspid annuloplasty was done for one group of patients based on surgeon's decision. Transthoracic echocardiography was done before and at a median follow-up of 4.71 months for all patients. The patients were divided into improved and unimproved TR groups, with the term "improved" signifying a reduction of at least one grade in TR severity.

**Results:** Tricuspid annuloplasty was performed on 65 (61.3%) patients. TR improvement was observed in 87.7% of patients in the TV repair group and 56.1% of patients in the no-TV repair group, indicating a significant difference ( $P < 0.001$ ). Tricuspid annulus diameter was not significantly different between the two groups ( $32.41 \pm 4.68$  mm in no-TV repair group and  $33.87 \pm 4.34$  mm in TV repair group,  $P = 0.128$ ). At follow-up with echocardiography, 80 (75.5%) patients were placed in the improved group and the majority of patients (71.3% vs. 30.8%;  $P < 0.001$ ) underwent tricuspid repair in the improved group. TV annuloplasty was correlated with reduced TR severity following left-sided valve surgery (odds ratio [OR]: 5.19, 95% CI: 1.70–15.85,  $P < 0.001$ ). TR changed from moderate to severe in 17 (17.1%) patients with no concomitant tricuspid repair, while only one patient (1.5%) with tricuspid repair showed an increased TR severity.

**Conclusion:** Tricuspid annuloplasty may be useful in patients who have moderate TR undergoing left-sided valve surgery regardless of the tricuspid annulus diameter, and it can play an effective role in the improvement of TR at mid-term follow-up.

**Keywords:** Left-sided valve surgery, Tricuspid annulus diameter, Tricuspid regurgitation, Tricuspid valve repair

**Cite this article as:** Abdollahi F, Lotfi-Tokaldany M, Jalali A, Ashrafi MM, Mohagheghi A, Sadeghian A, et al. Effect of tricuspid valve repair in patients with moderate tricuspid regurgitation undergoing left-sided valve surgery. Arch Iran Med. 2019;22(10):560–565.

Received: December 28, 2018, Accepted: May 12, 2019, ePublished: October 1, 2019

## Introduction

Tricuspid regurgitation (TR) is prevalent in patients with mitral valve diseases. It is reported that 14% to 27% of patients exhibit severe TR manifestations following mitral valve surgery in patients with rheumatic heart disease.<sup>1,2</sup> About 80% of patients with TR are functional because of right ventricular (RV) enlargement following annular dilation. Some risk factors of TR include congenital factors, trauma, endocarditis, rheumatic factors, pacemaker or defibrillator and iatrogenic causes.<sup>3</sup> The incidence of late TR diagnosed by echocardiography, either moderate or severe, in patients with rheumatic disease is considerably high (67%).<sup>4</sup> According to the current guidelines, the results of different studies are controversial regarding the benefits of TV repair for patients with moderate TR at the time of left-sided valve surgery. The most recent recommendation of the American College of Cardiology/American Heart Association Expert Committee is that

it is beneficial to repair moderate functional TR, with either tricuspid annular dilation or prior evidence of right heart failure at the time of left-sided valve surgery (Class IIa and level of evidence: B).<sup>5</sup> According to the European Society of Cardiology Expert Committee, surgery should be considered in patients with mild or moderate secondary TR with a severely dilated annulus ( $\geq 40$  mm) undergoing left-sided valve surgery.<sup>6</sup> A study by Navia et al showed that TV repair for moderate TR using left-sided valve surgery can be safe and appropriate to prevent right ventricle dysfunction.<sup>7</sup> The objective of this study is to compare the effect of TV repair on severity of TR at medium-term follow-up in patients with moderate TR undergoing left-sided valve surgery.

## Materials and Methods

### Study Patients

This study is a historical cohort carried out at the Tehran

\*Corresponding Author: Hakimeh Sadeghian, MD; Echocardiography Department, Dr. Shariati Hospital, North Karegar St., Tehran University of Medical Science, Tehran, Iran. Tel: +98 21 88026010; Fax: +98 21 88633039, Email: sadeghianhakimeh@yahoo.com

Heart Center, Tehran, Iran. In this study, patients with moderate functional TR underwent mitral and/or aortic valve surgery or repair from March 2011 to November 2016 at the Tehran Heart Center. We retrospectively identified all patients who had follow-up echocardiography in our institution and their pre-procedural and follow-up echocardiography data were available in the echocardiography data registry. Among this population, 106 surviving patients were recruited in this research. Patients who were candidate for revascularization were not included.

Concomitant TV annuloplasty (ring annuloplasty, 72.3% or Kay suture, 27.7%) was performed for patients. Also, 41 patients did not receive TV annuloplasty despite having moderate TR. The decision to repair the TV was finally made by the surgeon. Patients with structural TV disorders did not enter the study. The data of preoperative echocardiographic and procedural were collected using the patients' records and our institutional Echocardiography and Cardiac Surgery Data Registry. Data related to the follow-up echocardiography was also extracted from the echocardiography data registry. The median time between index surgery and follow-up echocardiography was 4.71 months (range: 2.1 to 17 months). The Institutional Review Board approved the study protocol, and all patients signed an informed consent before surgery.

### Echocardiography

All patients underwent preoperative echocardiography within a two-month period before surgery. Conventional echocardiographic examinations, including continuous-wave Doppler with color-flow imaging, M-mode, pulsed, and complete two-dimensional transthoracic echocardiography were performed using an ultrasonographic system (VIVID 7, Vingmed GE, Horten, Norway) with a 3.5-MHz transducer. Echocardiographic measurements were made according to current guidelines.<sup>8,9</sup> The degree of TR was assessed through the apical four-chamber view. It was graded according to the distal jet area as follows: mild TR indicating jet area less than 5 cm<sup>2</sup>; moderate TR indicating jet area from 5–10 cm<sup>2</sup>; and severe TR indicating jet area more than 10 cm<sup>2</sup>. A reduction of at least one grade in the severity of TR was regarded as improvement in TR severity. RV dilation was defined as increased diameter more than 35 mm at the mid-level of right ventricle.<sup>10</sup>

### Surgery

All surgeries were done with a vertical inline incision of sternotomy with the patient on standard cardiopulmonary bypass. Then, myocardium was protected with the administration of cold crystalloid cardioplegic solution or cold blood. The TV repair procedure was based on the surgeon's decision and included either the insertion of a Cosgrove-Edward annuloplasty band (Edwards Life

sciences, Irvine, CA, USA) or Kay suture annuloplasty.

### Statistical Analysis

The results are reported as means and standard deviations for the numerical variables. *T* test or the Mann-Whitney *U* was used to compare continuous variables. A *P* value less than 0.05 was considered significant. The patients were divided into two groups: 1) improved TR, if the patients demonstrated a reduction in TR severity from moderate to mild or to no TR; and 2) unimproved TR, if the severity of TR remained at moderate level or worsened to severe TR. A logistic regression was used to calculate odds ratio (OR) to estimate the effect of demographic, clinical, echocardiography and procedural variables on TR improvement. The potential confounding factors for the effect of TV repair on TR improvement were selected if they had relationship with both TR improvement and TV repair with a *P* value < 0.15 in univariable analysis or if they could be potentially considered a confounder according to the literature review. Thus, we identified the following variables as potential confounders: hypertension, chronic obstructive pulmonary disease, pre-procedural TV annulus diameter, ≥ moderate mitral valve stenosis, and type of surgery on the left side. The multiple logistic regressions method was used to adjust the effect of independent variables on the dependent variables.

### Results

One hundred and nine patients, comprising 35 (33.0%) males, were included. The mean age was 54.03 ± 12.61 years. Left-sided surgery included 47 (44.3%) cases of mitral valve replacement, 7 (6.6%) cases of aortic valve replacement, 36 (34.0%) cases of both aortic and mitral valve replacement, and 16 (15.1%) cases of mitral valve repair. All patients had moderate TR. Also, 65 (61.3%) patients underwent concomitant tricuspid annuloplasty. A comparison between the patients with/without TV repair is presented in Table 1. In the TV repair group, 87.7% had TR improvement while in the no-TV repair group, 56.1% had TR improvement, indicating a statistically significant difference (*P* < 0.001). Tricuspid annulus diameter showed no significant difference between the two groups (mean difference = 1.46, 95% CI: 0.31–3.23, *P* = 0.128). The entire study population was successfully followed-up for a median time of 4.71 months. At follow-up echocardiography, 75.5% of patients (*n* = 80) were placed in the improved TR group. The other 26 (24.5%) patients did not show improvement in TR severity and were categorized as the unimproved TR group. A comparison between these two groups is presented in Table 2. According to Table 2, the patients in the improved TR group had less hypertension. The frequency of ≥ moderate mitral valve stenosis as the pathologic reason for mitral valve surgery was higher in the improved TR patients (67.5% vs. 61.5%, *P* value = 0.033). No difference was found regarding the

**Table 1.** Demographic, Clinical, and Baseline Echocardiographic Characteristics of Study Patients

Characteristic	No-TV Repair (n = 41)	TV Repair (n = 65)	P Value
Age, year	52.02 ± 14.38	55.29 ± 11.28	0.221
Male gender, No. (%)	16 (39.0)	19 (29.29)	0.296
Past medical history			
Diabetes mellitus	5 (12.2)	6 (9.2)	0.746
Hypertension	12 (29.3)	5 (7.7)	0.003
Dyslipidemia	13 (31.7)	17 (26.2)	0.536
Cigarette smoking	2 (4.9)	3(4.6)	0.999
COPD	9 (22.0)	2 (3.1)	0.003
Atrial fibrillation	13 (40.6)	30 (57.7)	0.129
Global LV ejection fraction	50.62 ± 8.03	51.41 ± 5.18	0.542
Left atrial size	49.15 ± 8.77	51.80 ± 7.95	0.111
LV end-diastolic diameter	52.15 ± 8.29	53.14 ± 8.60	0.559
LV end-systolic diameter	35.07 ± 7.96	35.40 ± 7.13	0.827
Interventricular septum diameter	10.51 ± 2.66	10.25 ± 2.38	0.600
Posterior wall thickness	10.46 ± 2.41	10.00 ± 1.76	0.259
RV dilation (diameter >35 mm at the mid-level)	4 (9.8)	12 (18.5)	0.223
TAPSE	19.26 ± 4.77	18.41 ± 4.45	0.368
Systolic pulmonary artery pressure, mm Hg	50.95 ± 12.42	49.45 ± 13.12	0.568
Tricuspid valve annulus diameter, mm	32.41 ± 4.68	33.87 ± 4.34	0.128
Abnormal septum morphology	10 (24.4)	18 (27.7)	0.707
≥ Moderate LV systolic dysfunction	4 (9.8)	5 (7.7)	0.732
≥ Moderate mitral valve stenosis	22 (53.7)	48 (73.8)	0.033
≥ Moderate mitral valve regurgitation	26 (63.4)	46 (70.8)	0.429
≥ Moderate aortic valve stenosis	9(22.0)	15 (23.1)	0.893
≥ Moderate aortic valve regurgitation	18 (43.9)	28 (43.1)	0.933
TR improvement	23 (56.1)	57 (87.7)	<0.001

Abbreviations: COPD, chronic obstructive pulmonary disease; TV, tricuspid valve; LV, left ventricle; TAPSE, tricuspid annular plane systolic excursion; RV, right ventricle; PAP, pulmonary artery pressure, TR, tricuspid valve regurgitation.

left-sided operative category between the groups (Table 3). TV repair was performed in more patients in the improved TR group compared with the unimproved TR patients (71.3% vs. 30.8%, respectively;  $P$  value < 0.001). The severity of moderate TR changed to severe in 8 out of the total 106 cases (7.5%), 7 of whom were among the patients with no TV repair. Therefore, the frequency of worsening TR in patients with no concomitant TV repair was 17.1% (7 out of 41). Comparison between patients with/without TV repair showed that patients with TV repair had lower risk for worsening TR (odds ratio [OR] = 0.08, 95% CI: 0.01–0.64,  $P$  = 0.018). Figure 1 indicates the number of improvement, no change and worsening in each TV repair and no-TV repair groups.

To determine the independent effect of TV repair, we adjusted the relationship between TV repair and TR improvement by including the following variables in the multivariate logistic regression models: gender; history of hypertension and chronic obstructive pulmonary disease; interventricular septum diameter; TV annular diameter; severity of mitral valve stenosis (<moderate or ≥ moderate); TV repair and cardiopulmonary cross-clamp time. The result showed that TV annuloplasty was independently correlated with improvement of TR (OR: 5.576, 95% CI: 2.128, 14.612,  $P$  value < 0.001), after a median time of 4.71 months following left-sided surgery (Table 4).

## Discussion

In summary, after a median follow-up time of 4.71 months, many patients (75.5%) with moderate TR showed reduced TR severity following the surgery of left-sided valve. TV annuloplasty had an effective role in reduction of TR severity. TR grade changed from moderate to severe among 17.1% of those without concomitant TV repair, while only 1.5% of patients with TV repair were found to have an increased TR grade. TR improvement was significantly different between the two groups of with/without TV repair.

Multiple previous studies have addressed the clinical outcomes following left-sided valve or coronary revascularization surgeries. We observed that TV repair was significantly associated with decreased TR severity following left-sided valve surgery in patients who had moderate TR. Our findings confirm a study by Navia et al,<sup>11</sup> who reported that no-TV repair was correlated with increased TR severity in patients who had moderate TR with left-sided degenerative heart valve disease.

It is reported if TR is left untreated, that a considerable proportion of patients may shift from moderate to severe TR following left heart valve surgery. In studies by Matsuyama et al.<sup>12</sup> and Song et al.<sup>13</sup> on patients undergoing mitral surgery without TV repair, 16% for mild and 7.7% for moderate TR experienced moderate to severe TR during follow-up, respectively. It has been suggested that

**Table 2.** Demographic, Clinical, and Baseline Echocardiographic Characteristics of Study Groups

Characteristic	Total Patients (n = 106)	Improved TR (n = 80)	Unimproved TR (n = 26)	OR (95% CI)	P Value
Age, year	54.03 ± 12.61	54.99 ± 12.45	51.08 ± 12.86	1.03 (0.99–1.06)	0.171
Male gender, No. (%)	35 (33.0)	27 (33.8)	8 (30.8)	1.15 (0.44–2.97)	0.779
BMI	25.86 ± 3.98	26.01 ± 3.95	25.37 ± 4.10	1.04 (0.93–1.17)	0.476
Past medical history					
Diabetes mellitus	11 (10.4)	10 (12.5)	1 (3.8)	0.28 (0.03–8.30)	0.236
Hypertension	17 (16.3)	9 (11.3)	8 (30.8)	3.51 (1.19–10.36)	0.023
Dyslipidemia	30 (28.3)	24 (30.0)	6 (23.1)	0.80 (0.25–1.96)	0.497
Cigarette smoking	5 (4.7)	3 (3.8)	2 (7.7)	0.47 (0.07–2.96)	0.420
COPD	11 (10.4)	6 (7.5)	5 (19.2)	0.34 (0.09–1.23)	0.100
Atrial fibrillation	52 (49.1)	40 (50.0)	12 (46.2)	0.86 (0.35–2.08)	0.733
Global LV ejection fraction	51.10 ± 6.41	51.38 ± 6.32	50.25 ± 6.74	1.03 (0.96–1.10)	0.438
Left atrial size	50.77 ± 8.34	51.14 ± 8.66	49.65 ± 7.29	1.02 (0.97–1.08)	0.430
LV end-diastolic diameter	52.75 ± 8.45	52.56 ± 8.28	53.35 ± 9.13	0.99 (0.94–1.04)	0.680
LV end-systolic diameter	35.27 ± 7.43	35.63 ± 7.04	34.19 ± 8.57	1.03 (0.97–1.09)	0.392
Interventricular septum diameter	10.35 ± 2.48	10.54 ± 2.54	9.76 ± 2.26	1.06 (0.94–1.43)	0.175
Posterior wall thickness	10.18 ± 2.05	10.28 ± 2.09	9.88 ± 1.93	1.11 (0.88–1.40)	0.399
RV dilation (diameter >35 mm at the mid-level)	16 (15.1)	13 (16.3)	3 (11.5)	0.67 (0.18–2.57)	0.562
TAPSE	18.74 ± 4.57	18.83 ± 4.61	18.42 ± 5.17	1.02 (0.92–1.13)	0.695
Systolic PAP, mm Hg	50.02 ± 12.82	50.13 ± 12.40	49.68 ± 14.31	1 (0.97–1.04)	0.879
Tricuspid valve annulus, mm	33.25 ± 4.50	33.61 ± 4.42	32.15 ± 4.67	1.08 (0.97–1.20)	0.154
Abnormal septum morphology					
≥ Moderate LV systolic dysfunction	9 (8.5)	5 (6.3)	4 (15.4)	2.73 (0.67–11.04)	0.160
≥ Moderate mitral stenosis	70 (66.0)	54 (67.5)	16 (61.5)	0.77 (0.31–1.93)	0.578
≥ Moderate mitral regurgitation	72 (67.9)	54 (67.5)	18 (69.2)	1.08 (0.42–2.82)	0.870
≥ Moderate aortic stenosis	24 (22.6)	20 (25.0)	4 (15.4)	0.55 (0.17–1.77)	0.314
≥ Moderate aortic regurgitation	46 (43.4)	32 (40.0)	14 (53.8)	1.75 (0.72–4.27)	0.219

Abbreviations: COPD, chronic obstructive pulmonary disease; BMI, body mass index; LV, left ventricle; TAPSE, tricuspid annular plane systolic excursion; RV, right ventricle; PAP, pulmonary artery pressure.

**Table 3.** Procedural Characteristics of the Study Groups

Characteristic	Improved TR (n = 80)	No improved TR (n = 26)	OR (95% CI)	P Value
Tricuspid repair	57 (71.3)	8 (30.8)	5.58 (2.13–14.61)	<0.001
Left-sided surgery				
Mitral replacement	37 (46.3)	10 (38.5)	-	0.718
Aortic replacement	6 (7.5)	1 (3.8)	1.63 (0.17–15.07)	0.671
Mitral and aortic replacement	25 (31.3)	11 (42.3)	0.61 (0.23–1.66)	0.337
Mitral annuloplasty	12 (14.8)	4 (14.3)	0.81 (0.21–3.07)	0.757
Cardiopulmonary cross-clamp Time	67 (48, 90)	86 (51, 112)	0.99 (0.98–1)	0.155
Cardiopulmonary bypass time	100 (80, 150)	110 (81, 180)	0.99 (0.99–1)	0.155

Abbreviations: TR, tricuspid regurgitation.

Categorical variables are presented as number (%) and continuous variables are presented as median (25%, 75% percentile).

prophylactic TV repair for moderate functional TR at the time of mitral valve replacement reduces complication rates and increases 30-day and 2-year survival compared with contemporaneous patients undergoing redo surgery for TV repair who had their initial mitral surgery without concomitant TV repair.<sup>14</sup> TV repair also had a beneficial effect on postop TV function in patients who had mild TR and changed to moderate TR undergoing MV replacement for rheumatic MV diseases, regardless of whether preoperative TR degree was moderate or mild.<sup>15</sup> The findings of the present study support the results of recent reports in favor of benefits of TV repair at the time of left-sided valve surgery.

A study by Dreyfus et al concluded that the positive effect of TV annuloplasty on functional status is related

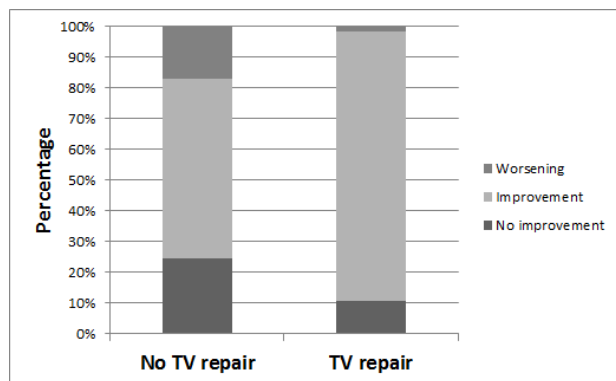
to the degree of TV annular dilation and is irrespective of the grade of regurgitation. In their study,<sup>16</sup> in patients with dilated TV annulus in terms of an annular diameter ≥ 70 mm, the severity of TR increased > 2 grades in many patients (48%) in the mitral valve repair group, which was much higher compared to 2% in the mitral valve repair plus TV annuloplasty group. They concluded that TV dilation was more valid compared to TR grade in secondary assessment of TV disease. It is worthy of note that echocardiography was not the method employed to measure the TV annulus in their study and the TV annulus diameter was measured during surgery with a ruler from the anteroseptal commissure to the anteroposterior commissure. We included patients who had moderate TR undergoing left-sided valve surgery and observed that



**Table 4.** Unadjusted and Adjusted Effect of TV Repair on Improvement in TR Severity after Left Sided Valve Surgery in Patients with Concomitant Moderate or Severe TV Regurgitation

	OR (95% CI)	P
<b>Unadjusted</b>		
TV repair vs. no-TV repair	5.58 (2.13–14.61)	<0.001
<b>Adjusted</b>		
TV repair vs. no-TV repair	5.576 (2.128–14.612)	<0.001
Hypertension	0.52 (0.14–1.85)	0.312
COPD	0.75 (0.17–3.40)	0.708
TV annulus diameter	1.07 (0.95–1.21)	0.255
≥ Moderate mitral stenosis	1.28 (0.40–4.10)	0.673
<b>Type of left side surgery</b>		
Mitral replacement	Reference	-
Aortic replacement	3.14 (0.26–38.09)	0.368
Both replacements	0.44 (0.13–1.46)	0.178
Mitral annuloplasty	0.52 (0.11–2.46)	0.413

Abbreviations: TV, tricuspid valve; COPD, chronic obstructive pulmonary disease.

**Figure 1.** Frequency of Improvement, No Change and Worsening in Each TV Repair and No-TV Repair Groups.

the diameter of TV annulus did not differ between the patients with/without TV repair ( $33.87 \pm 4.34$  vs.  $32.41 \pm 4.68$  mm, respectively). Dreyfus et al<sup>16</sup> reported that in patients undergoing left-sided valve surgery, TV repair is indicated for even mild TR in the case of severe annular dilation; the results of our study demonstrated that in patients with moderate TR undergoing left-sided valve surgery, TV repair improves post-operative TR severity regardless of TV annulus diameter.

The results of our previous study on patients who underwent isolated coronary artery bypass surgery showed that TR severity was improved in 64% of patients following coronary artery bypass surgery, whereas it remained unchanged or even worse in others.<sup>17</sup> Patients with inferior myocardial infarction had no improvement in TR while patients without inferior infarction had significant TR regression after coronary artery bypass surgery.

### Limitation

One of the limitations of this study is the retrospective nature; we only included patients who survived and

underwent follow-up echocardiography in our institution. Therefore, not including data from patients who died before follow-up echocardiography or those who survived but did not undergo follow-up echo in our institution may affect the final results. The second limitation is that although we showed the increase of reduced postoperative TR severity in medium-term follow-up after TV repair, we could not extend our follow-up duration to demonstrate the effective role of TV repair in change of late TR severity. In conclusion, TV annuloplasty had a significant independent role in reduction of TR severity after left-sided valve surgery, regardless of the diameter of TV annulus. TR grade changed from moderate to severe in the majority of patients with no concomitant TV repair while only one patient in the TV repair group showed increased TR grade.

### Authors' Contribution

All the authors contributed equally to the study.

### Conflict of Interest Disclosures

None declared.

### Ethical Statement

This protocol of study was approved by the Institutional Review Board. All patients were informed and given written consent form.

### References

- Izumi C, Iga K, Konishi T. Progression of isolated tricuspid regurgitation late after mitral valve surgery for rheumatic mitral valve disease. *J Heart Valve Dis.* 2002;11(3):353-6.
- Kwak JJ, Kim YJ, Kim MK, Kim HK, Park JS, Kim KH, et al. Development of tricuspid regurgitation late after left-sided valve surgery: A single-center experience with long-term echocardiographic examinations. *Am Heart J.* 2008;155(4):732-7. doi: 10.1016/j.ahj.2007.11.010.
- Topilsky Y, Khanna A, Le Tourneau T, Park S, Michelena H, Suri R, et al. Clinical context and mechanism of functional tricuspid regurgitation in patients with and without pulmonary hypertension. *Circ Cardiovasc Imaging.* 2012;5(3):314-23. doi: 10.1161/CIRCIMAGING.111.967919.
- Porter A, Shapira Y, Wurzel M, Sulkes J, Vaturi M, Adler Y, et al. Tricuspid regurgitation late after mitral valve replacement: Clinical and echocardiographic evaluation. *J Heart Valve Dis.* 1999;8(1):57-62.
- Nishimura RA, Otto CM, Bonow RO, Carabello BA, Erwin JP 3rd, Guyton RA, et al. 2014 aha/acc guideline for the management of patients with valvular heart disease: A report of the american college of cardiology/american heart association task force on practice guidelines. *J Thorac Cardiovasc Surg.* 2014;148(1):e1-e132. doi: 10.1016/j.jtcvs.2014.05.014.
- Vahanian A, Alfieri O, Andreotti F, Antunes MJ, Baron-Esquivias G, Baumgartner H, et al. Guidelines on the management of valvular heart disease (version 2012): The joint task force on the management of valvular heart disease of the european society of cardiology (esc) and the european association for cardio-thoracic surgery (eacts). *Eur J Cardiothorac Surg.* 2012;42(4):S1-44. doi: 10.1093/ejcts/ezs455.
- Navia JL, Brozzi NA, Klein AL, Ling LF, Kittayarak C, Nowicki ER, et al. Moderate tricuspid regurgitation with left-sided degenerative heart valve disease: to repair or not to repair? *Ann Thorac Surg.* 2012;93(1):59-67. doi: 10.1016/j.athoracsur.2011.08.037.
- Lang RM, Bierig M, Devereux RB, Flachskampf FA, Foster E,

- Pelikka PA, et al. Recommendations for chamber quantification: A report from the American Society of Echocardiography's guidelines and standards committee and the chamber quantification writing group, developed in conjunction with the European Association of Echocardiography, a branch of the European Society of Cardiology. *J Am Soc Echocardiogr.* 2005;18(12):1440-63.
9. Zoghbi WA, Enriquez-Sarano M, Foster E, Grayburn PA, Kraft CD, Levine RA, et al. Recommendations for evaluation of the severity of native valvular regurgitation with two-dimensional and Doppler echocardiography. *J Am Soc Echocardiogr.* 2003;16(7):777-802. Doi: 10.1016/S0894-7317(03)00335-3.
  10. Lang RM, Badano LP, Mor-Avi V, Afilalo J, Armstrong A, Ernande L, et al. Recommendations for cardiac chamber quantification by echocardiography in adults: an update from the American Society of Echocardiography and the European Association of Cardiovascular Imaging. *J Am Soc Echocardiogr.* 2015;28(1):1-39.e14. doi: 10.1016/j.echo.2014.10.003.
  11. Navia JL, Brozzi NA, Klein AL, Ling LF, Kittayarak C, Nowicki ER, et al. Moderate tricuspid regurgitation with left-sided degenerative heart valve disease: To repair or not to repair? *Ann Thorac Surg.* 2012;93(1):59-67. doi: 10.1016/j.athoracsur.2011.08.037.
  12. Matsuyama K, Matsumoto M, Sugita T, Nishizawa J, Tokuda Y, Matsuo T. Predictors of residual tricuspid regurgitation after mitral valve surgery. *Ann Thorac Surg.* 2003;75(6):1826-8. doi:10.1016/s0003-4975(03)00028-6.
  13. Song H, Kim MJ, Chung CH, Choo SJ, Song MG, Song JM, et al. Factors associated with development of late significant tricuspid regurgitation after successful left-sided valve surgery. *Heart.* 2009;95(11):931-6. doi: 10.1136/hrt.2008.152793.
  14. Teman NR, Huffman LC, Krajacic M, Pagani FD, Haft JW, Bolling SF. "Prophylactic" tricuspid repair for functional tricuspid regurgitation. *Ann Thorac Surg.* 2014;97(5):1520-4. doi: 10.1016/j.athoracsur.2013.11.049.
  15. Kim JB, Yoo DG, Kim GS, Song H, Jung SH, Choo SJ, et al. Mild-to-moderate functional tricuspid regurgitation in patients undergoing valve replacement for rheumatic mitral disease: The influence of tricuspid valve repair on clinical and echocardiographic outcomes. *Heart.* 2012;98(1):24-30. doi: 10.1136/heartjnl-2011-300403
  16. Dreyfus GD, Corbi PJ, Chan KM, Bahrami T. Secondary tricuspid regurgitation or dilatation: Which should be the criteria for surgical repair? *Ann Thorac Surg.* 2005;79(1):127-32. Doi: 10.1016/j.athoracsur.2004.06.057.
  17. Sadeghian H, Karimi A, Eslami B, Lotfi-Tokaldany M, Sahebjam M, Zoroufian A, et al. Impact of isolated coronary artery bypass grafting on non-organic tricuspid regurgitation severity. *J Teh Univ Heart Ctr* 2009;4:226-229.